



Age-Related Macular Degeneration

Sharon Parmet; Cassio Lynn; Richard M. Glass

JAMA. 2006;295(20):2438 (doi:10.1001/jama.295.20.2438)

<http://jama.ama-assn.org/cgi/content/full/295/20/2438>

Online article and related content
current as of November 22, 2009.

Supplementary material

Spanish PDF

<http://jama.ama-assn.org/cgi/content/full/295/20/2438/DC1>

Correction

[Contact me if this article is corrected.](#)

Citations

[Contact me when this article is cited.](#)

Topic collections

Ophthalmology; Ophthalmological Disorders; Macular Degeneration;
JAMA Patient Page

[Contact me when new articles are published in these topic areas.](#)

Related Articles published in
the same issue

A 76-Year-Old Man With Macular Degeneration
Jorge G. Arroyo. *JAMA*. 2006;295(20):2394.

Subscribe

<http://jama.com/subscribe>

Email Alerts

<http://jamaarchives.com/alerts>

Permissions

permissions@ama-assn.org

<http://pubs.ama-assn.org/misc/permissions.dtl>

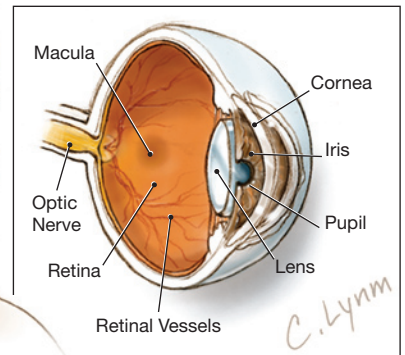
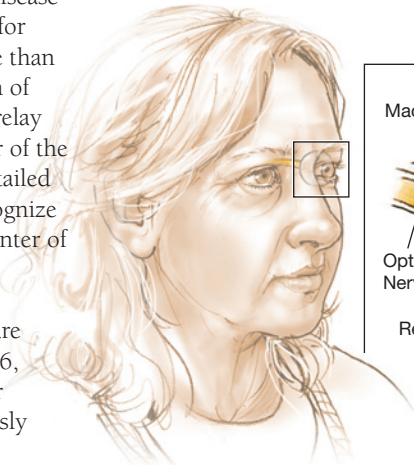
Reprints/E-prints

reprints@ama-assn.org

Age-Related Macular Degeneration

Age-related macular degeneration (AMD) is a disease of the eye that is the leading cause of blindness for people aged 65 years and older and affects more than 10 million Americans. AMD is caused by a deterioration of the **retina**—the layer of the eye that contains cells that relay images through the **optic nerve** to the brain. The center of the retina is called the **macula** and is responsible for the detailed central vision that allows people to read, drive, and recognize faces. If the macula starts to break down, areas in the center of the visual field start to look blurred.

Risk factors for AMD include older age, white race, and smoking. There is no cure for AMD, but therapies are available that can slow the disease. The May 24/31, 2006, issue of JAMA includes an article on age-related macular degeneration. This Patient Page is based on one previously published in the November 19, 2002, issue of JAMA.



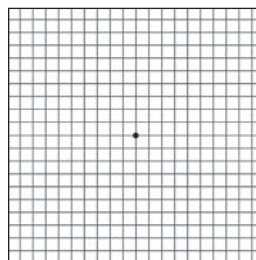
TYPES OF AGE-RELATED MACULAR DEGENERATION

There are 2 types of AMD: wet and dry. **Dry AMD** is more common and is associated with small, yellow deposits (**drusen**) in the macula. Dry AMD causes the macula to lose its function. The most common symptom of dry AMD is blurred central vision that worsens slowly. If dry AMD affects only one eye, symptoms may not be noticeable. **Wet AMD** accounts for approximately 15% of all cases of the disease. In wet AMD, abnormal blood vessels beneath the macula start to leak fluid, causing the retina to become distorted. This type of AMD can be severe and rapid. A common symptom of wet AMD is that straight lines appear wavy, and central vision degrades rapidly. Laser therapy to prevent the blood vessels from leaking is one form of therapy for wet AMD that your eye doctor may recommend. Unfortunately, recurrences after laser treatment are common.

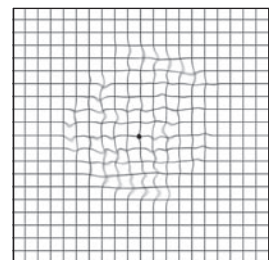
EVALUATION

A screening eye examination, including detailed examination of the retina, is recommended for all persons 40 years or older. If your eye doctor discovers drusen or other signs of AMD, it is important to have frequent eye examinations. Your eye doctor can provide you with an **Amsler grid** (a piece of graph paper with thick, dark lines) that you can use to test your vision each day. If the lines appear wavy or distorted, you should see your eye doctor immediately because it may be a sign of wet AMD. Your eye doctor may recommend the daily use of zinc and antioxidant vitamins (vitamin C, vitamin E, and beta carotene), which have been shown to reduce the risk of developing more severe forms of AMD.

Appearance of Amsler Grid With Normal Vision



Appearance of Amsler Grid With Macular Degeneration



FOR MORE INFORMATION

- National Eye Institute
www.nei.nih.gov
- Macular Degeneration Partnership
www.macd.net

INFORM YOURSELF

To find this and previous JAMA Patient Pages, go to the Patient Page link on JAMA's Web site at www.jama.com.

Sources: National Eye Institute, American Academy of Ophthalmology, Macular Degeneration Partnership, American Macular Degeneration Foundation, Macular Degeneration Network

Sharon Parmet, MS, Writer
Cassio Lynn, MA, Illustrator
Richard M. Glass, MD, Editor

The JAMA Patient Page is a public service of JAMA. The information and recommendations appearing on this page are appropriate in most instances, but they are not a substitute for medical diagnosis. For specific information concerning your personal medical condition, JAMA suggests that you consult your physician. This page may be photocopied noncommercially by physicians and other health care professionals to share with patients. To purchase bulk reprints, call 203/259-8724.

