



## Electrocardiograms

Sharon Parmet; Cassio Lynn; Richard M. Glass

*JAMA*. 2006;296(10):1314 (doi:10.1001/jama.296.10.1314)

Online article and related content  
current as of July 11, 2009.

<http://jama.ama-assn.org/cgi/content/full/296/10/1314>

Supplementary material

Spanish PDF

<http://jama.ama-assn.org/cgi/content/full/296/10/1314/DC1>

Correction

[Contact me if this article is corrected.](#)

Citations

[Contact me when this article is cited.](#)

Topic collections

Pacemakers/ Defibrillators; JAMA Patient Page; Cardiovascular Intervention

[Contact me when new articles are published in these topic areas.](#)

Related Articles published in  
the same issue

Risk of Aborted Cardiac Arrest or Sudden Cardiac Death During Adolescence in the Long-QT Syndrome

Jenny B. Hobbs et al. *JAMA*. 2006;296(10):1249.

Subscribe

<http://jama.com/subscribe>

Email Alerts

<http://jamaarchives.com/alerts>

Permissions

[permissions@ama-assn.org](mailto:permissions@ama-assn.org)

<http://pubs.ama-assn.org/misc/permissions.dtl>

Reprints/E-prints

[reprints@ama-assn.org](mailto:reprints@ama-assn.org)

# Electrocardiograms

An **electrocardiogram (ECG or EKG)** is a recording of the electrical activity of the heart made from **electrodes** (electrical conductors) placed on the surface of the skin, usually on each arm and leg and across the chest. The function of the heart in expanding and contracting to pump blood to the body is controlled by small electrical impulses within the heart. These impulses can be detected by electrodes on the skin and transmitted to the electrocardiogram machine by wires. The impulses are then translated into peaks and valleys or squiggles by the ECG machine, which includes a pen that moves up and down over a long strip of paper passing through the machine at a steady rate. Each **cardiac cycle**, or heartbeat, is recorded as a particular series of peaks and valleys.

The September 13, 2006, issue of *JAMA* includes an article about prolongation of an ECG interval, the QT interval. Some drugs and genetic conditions can prolong the QT interval; in a few people this can lead to dangerous abnormalities of heart rhythm. This Patient Page is based on one previously published in the April 23/30, 2003, issue of *JAMA*.

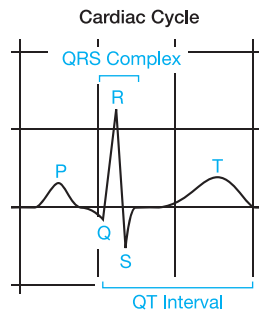
## HOW ARE ELECTROCARDIOGRAMS USED?

Electrocardiograms are useful in indicating

- If there are any irregular heartbeats or **arrhythmias** (abnormal rhythms)
- If there is a decreased supply of blood or oxygen to the heart
- Whether a heart attack has occurred or is likely to be occurring
- What part of the heart may have been damaged
- If **myocarditis** (inflammation of the heart) is present

The ECG records the electrical activity of the heart that triggers the heart muscle to contract. A normal ECG pattern is made up of several peaks and valleys representing a single cardiac cycle. A cardiac cycle consists of a single heartbeat, when the heart fills with blood and then contracts to push the blood throughout the body. A specialized part of the heart called the **sinoatrial (SA) node** signals the beginning of a cycle. In the heart's **atria** (chambers where blood is temporarily held before passing into **ventricles** where it is pumped out), an electrical change causes the ECG pen to move and then return to the neutral position. The wave produced on the ECG is called a **P wave**.

Next, the electrical impulse travels through the **atrioventricular (AV) node** to reach the muscle cells of the ventricles, causing them to **depolarize** (change their electrical charge). Because the walls of the ventricles are much larger than those of the atria, the amount of electrical change is greater, and the pen draws a larger wave. When the electrical change finishes, the pen returns to the neutral position, leaving a mark called the **QRS complex**, which usually consists of a **Q wave**, an **R wave**, and an **S wave**. The electrical changes occurring as the ventricular muscle fibers **repolarize** (recover their electrical charge) produces a **T wave** as the pen moves again, ending the pattern created by a single cardiac cycle. The ECG peaks and valleys thus indicate whether the electrical impulses are traveling through the heart at the right speed in the right order.



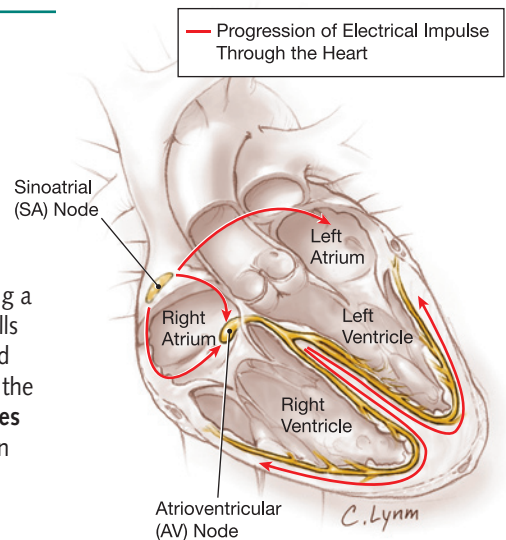
Sources: American Heart Association, American Medical Association Encyclopedia of Medicine

Sharon Parmet, MS, Writer

Cassio Lynn, MA, Illustrator

Richard M. Glass, MD, Editor

The JAMA Patient Page is a public service of JAMA. The information and recommendations appearing on this page are appropriate in most instances, but they are not a substitute for medical diagnosis. For specific information concerning your personal medical condition, JAMA suggests that you consult your physician. This page may be photocopied noncommercially by physicians and other health care professionals to share with patients. To purchase bulk reprints, call 203/259-8724.



## FOR MORE INFORMATION

- American Heart Association  
[www.americanheart.org](http://www.americanheart.org)

## INFORM YOURSELF

To find this and previous JAMA Patient Pages, go to the Patient Page link on JAMA's Web site at [www.jama.com](http://www.jama.com). A Patient Page on cardiopulmonary resuscitation was published in the January 19, 2005, issue, one on cardiac arrest was published in the January 4, 2006, issue, and one on automated external defibrillators was published in the August 9, 2006, issue.

