



## Renal Artery Stenosis

Carolyn J. Hildreth; Cassio Lynn; Richard M. Glass

*JAMA*. 2008;300(17):2084 (doi:10.1001/jama.300.17.2084)

<http://jama.ama-assn.org/cgi/content/full/300/17/2084>

Online article and related content  
current as of November 10, 2009.

Supplementary material

Spanish PDF

<http://jama.ama-assn.org/cgi/content/full/300/17/2084/DC1>

Correction

[Contact me if this article is corrected.](#)

Citations

[Contact me when this article is cited.](#)

Topic collections

Renal Diseases; Renal Diseases, Other; JAMA Patient Page

[Contact me when new articles are published in these topic areas.](#)

Subscribe

<http://jama.com/subscribe>

Email Alerts

<http://jamaarchives.com/alerts>

Permissions

[permissions@ama-assn.org](mailto:permissions@ama-assn.org)

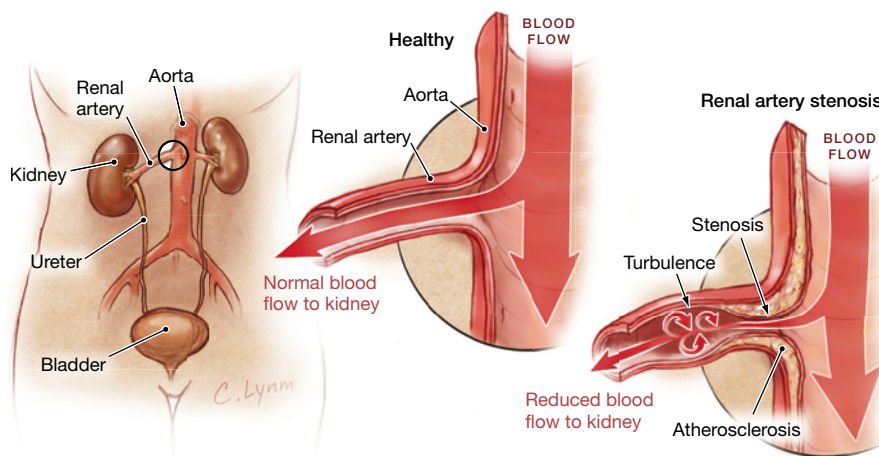
<http://pubs.ama-assn.org/misc/permissions.dtl>

Reprints/E-prints

[reprints@ama-assn.org](mailto:reprints@ama-assn.org)

# Renal Artery Stenosis

**R**enal artery stenosis (RAS) is a narrowing of the arteries to one or both of the kidneys that can cause **hypertension** (high blood pressure) and, sometimes, reduced kidney function and size (**atrophy**). It occurs more commonly in older people with **atherosclerosis** (hardening of the arteries with plaque buildup, leading to narrowing of the channel where the blood flows). Hypertension caused by RAS is called **secondary hypertension**. This means that, unlike **essential** or **primary hypertension** (the most common form of high blood pressure, which does not have a specific known cause), secondary hypertension does have a specific cause. In some cases, diagnosing and treating RAS can result in decreasing or eliminating the need to take medication for hypertension. The narrowing of the kidney arteries in RAS is usually due to atherosclerosis; more rarely it can be caused by abnormal growth of tissue within the wall of the artery. The latter condition, called **fibromuscular dysplasia**, is potentially curable and is more common in women and younger age groups but can also occur later in life. When atherosclerosis is the cause of RAS, it is especially important to be evaluated and treated for related diseases of the heart and brain, since they are also susceptible to narrowed arteries. Atherosclerosis in those organs can lead to heart attack or stroke. The November 5, 2008, issue of *JAMA* includes an article about an 82-year-old woman with hypertension and renal artery stenosis.



## TREATMENT

- Take medication to control blood pressure. This may require 3 or more different drugs.
- Don't smoke.
- Control diabetes if it is present.
- Control cholesterol, taking medications if necessary.
- **Renal (kidney) artery angioplasty** (insertion of a balloon into the narrowed artery to open it) and **stenting** (inserting a tube inside the artery to hold the walls open) are only done if blood pressure cannot be controlled with medications or if blood tests indicate a significant worsening of kidney function.

## FOR MORE INFORMATION

- Medline Plus  
[www.nlm.nih.gov/medlineplus](http://www.nlm.nih.gov/medlineplus)

## INFORM YOURSELF

To find this and other JAMA Patient Pages, go to the Patient Page link on JAMA's Web site at [www.jama.com](http://www.jama.com). Many are available in English, Spanish, and French. A Patient Page on hypertension and kidney disease was published in the November 20, 2002, issue.

## SYMPTOMS

- Most often, renal artery stenosis does not cause any specific symptoms. Rarely, a person may have symptoms related to high blood pressure such as fatigue, headache, or dizziness.

## DIAGNOSIS

- New onset of high blood pressure in someone younger than 35 or older than 55
- Worsening control of previously well-controlled hypertension, or very high blood pressure, especially if it is affecting other organs in the body
- Blood tests and urine tests to evaluate kidney function
- **Kidney ultrasound** visualizes the size and structure of the kidney by recording the echoes of sound waves. **Doppler ultrasound** measures the speed of the blood flow within the arteries to the kidney.
- **Magnetic resonance arteriogram** and **computed tomographic angiography** are imaging studies that use **contrast medium** (special dye) to produce a 3-dimensional image of the kidney and its blood vessels.

Source: *Harrison's Principles of Internal Medicine*, 17th edition

Carolyn J. Hildreth, MD, Writer

Cassio Lynn, MA, Illustrator

Richard M. Glass, MD, Editor

The JAMA Patient Page is a public service of JAMA. The information and recommendations appearing on this page are appropriate in most instances, but they are not a substitute for medical diagnosis. For specific information concerning your personal medical condition, JAMA suggests that you consult your physician. This page may be photocopied noncommercially by physicians and other health care professionals to share with patients. To purchase bulk reprints, call 312/464-0776.

