



Cataracts

Carolyn J. Hildreth; Alison E. Burke; Richard M. Glass

Online article and related content
current as of February 10, 2010.

JAMA. 2009;301(19):2060 (doi:10.1001/jama.301.19.2060)

<http://jama.ama-assn.org/cgi/content/full/301/19/2060>

Supplementary material

Spanish PDF

<http://jama.ama-assn.org/cgi/content/full/301/19/2060/DC1>

Correction

[Contact me if this article is corrected.](#)

Citations

[Contact me when this article is cited.](#)

Topic collections

Ophthalmology; Ophthalmological Disorders; Cataracts/ Lens;
Ophthalmological Procedures; Ophthalmological Procedures, Other;
JAMA Patient Page

[Contact me when new articles are published in these topic areas.](#)

Related Articles published in
the same issue

Association Between Tamsulosin and Serious Ophthalmic Adverse
Events in Older Men Following Cataract Surgery

Chaim M. Bell et al. *JAMA*. 2009;301(19):1991.

Subscribe

<http://jama.com/subscribe>

Email Alerts

<http://jamaarchives.com/alerts>

Permissions

permissions@ama-assn.org

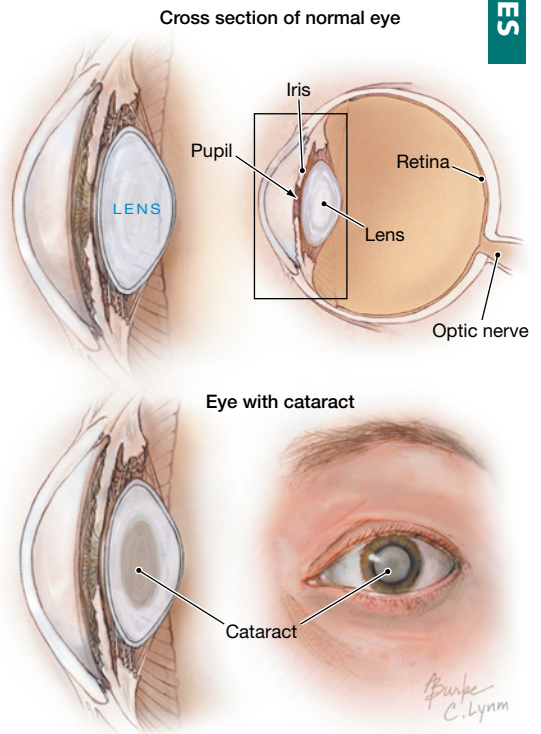
<http://pubs.ama-assn.org/misc/permissions.dtl>

Reprints/E-prints

reprints@ama-assn.org

Cataracts

Cataracts are the leading cause of blindness worldwide. They can occur at any age, but most cataracts occur in people over 40 years old and are considered an age-related eye disease. A cataract is a clouding of the **lens** in the eye. The lens is a transparent disc located behind the **pupil** (dark opening in the center of the eye) and the **iris** (the distinctly colored part around the pupil). The lens helps to focus light on the **retina**, located at the back of the eye, where nerve signals are created and transmitted to the brain to create the visual image for what is seen. The lens is made of water, proteins, and polysaccharides. As we age, some of the proteins begin to clump together and the area in the lens associated with these proteins becomes cloudy. This results in a gradual change in the lens from transparent to yellowish brown. Light passing through a lens with a cataract is not clearly focused on the retina, so images received from the brain may be blurred or brown tinged. Cataracts may progress over a number of years and do not require treatment unless they compromise vision or prevent examination or treatment for other eye disorders. The May 20, 2009, issue of *JAMA* includes an article about cataract surgery.



FACTORS CONTRIBUTING TO CATARACT DEVELOPMENT

- Normal aging
- Diabetes
- Smoking
- Excessive alcohol use
- Eye injury
- Cumulative exposure to the ultraviolet (UV) radiation from sunlight
- Certain medications, particularly long-term use of corticosteroids

SYMPTOMS CAUSED BY CATARACTS

- Blurred vision
- Brown-tinted vision
- Colors appear faded
- Halo around objects
- Glare around lights
- Poor night vision
- Double vision

PREVENTION

- If you smoke, quit.
- Keep your blood sugar under control if you have diabetes.
- Wear full-spectrum UV protection sunglasses on your eyes when outdoors, or a wide-brimmed hat to shade your eyes from the sun.
- Have a dilated eye examination by an **ophthalmologist** (a physician specializing in diseases of the eyes) beginning at age 40, then have regular eye examinations guided by the advice of your ophthalmologist.

TREATMENT

- A complete medical history and ophthalmologic examination is required for diagnosis so recommendations can be made for the best treatment plan for each individual.
- A change in eyeglass prescription may help for an early cataract.
- Surgery to remove the cataract, usually replacing it with an intraocular lens, a clear plastic device that requires no care and becomes an integral part of the eye

FOR MORE INFORMATION

- National Eye Institute
www.nei.nih.gov/health/cataract/cataract_facts.asp
- American Academy of Ophthalmology
www.geteyesmart.org/diseases

INFORM YOURSELF

To find this and other JAMA Patient Pages, go to the Patient Page link on JAMA's Web site at www.jama.com. Many are available in English and Spanish. A Patient Page on causes of visual impairment was published in the October 15, 2003, issue; one on age-related macular degeneration in the May 24/31, 2006, issue; and one on retinopathy in the January 5, 2005, issue.

Sources: National Eye Institute, American Academy of Ophthalmology

Carolyn J. Hildreth, MD, Writer

Alison E. Burke, MA, Illustrator

Richard M. Glass, MD, Editor

The JAMA Patient Page is a public service of JAMA. The information and recommendations appearing on this page are appropriate in most instances, but they are not a substitute for medical diagnosis. For specific information concerning your personal medical condition, JAMA suggests that you consult your physician. This page may be photocopied noncommercially by physicians and other health care professionals to share with patients. To purchase bulk reprints, call 312/464-0776.

