

both of which have evidence-based clinical practice guidelines to guide patient care.

Although differences in rates of coronary artery bypass graft (CABG) surgery may represent disparities in care, other factors require consideration. Because procedure appropriateness is unknown, it is unclear whether the CABG rates represent undertreatment of blacks, overtreatment of whites, appropriate care of one group or the other, or some combination of these processes. Basic questions concerning treatment indications, contraindications, influence of other patient confounders, availability of CABG, and patient preferences must be explored before we can be certain that racial differences in CABG represent disparities in care. Without these data, we have simply a report of a difference and no context within which to interpret it.

We believe that a prerequisite to the realization of equity in health care is the dispassionate, objective study of racial variations in treatment, including in-depth investigation of the breadth of, consistency of, and factors that accompany racial disparities where they exist. Such efforts to assess quality of care represent an important first step in the process toward identifying and eliminating racial disparities in care. Such research can help ensure that the US health care system realizes its commitment to providing high-quality care to all patients, irrespective of their race or ethnicity.

Saif S. Rathore, MPH
 Harlan M. Krumholz, MD, SM
 Section of Cardiovascular Medicine
 Department of Internal Medicine
 Yale University School of Medicine
 New Haven, Conn
 Frederick A. Masoudi, MD, MSPH
 Edward P. Havranek, MD
 Division of Cardiology
 Department of Medicine
 Denver Health Medical Center
 Denver, Colo

1. Jencks SF, Huff ED, Cuerdon T. Change in the quality of care delivered to Medicare beneficiaries, 1998-1999 to 2000-2001. *JAMA*. 2003;289:305-312.

2. Rathore SS, Berger AK, Weinfurt KP, et al. Race, sex, poverty and the medical treatment of acute myocardial infarction in the elderly. *Circulation*. 2000;102:642-648.

3. Schneider EC, Zaslavsky AM, Epstein AM. Racial disparities in the quality of care for enrollees in Medicare managed care. *JAMA*. 2002;287:1288-1294.

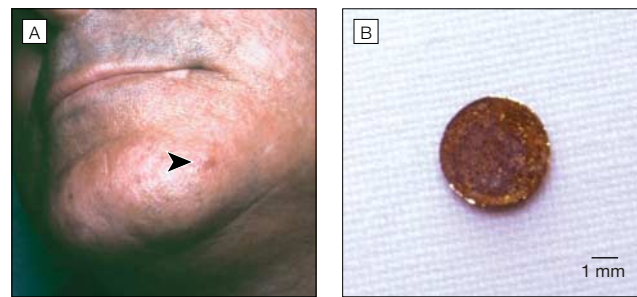
RESEARCH LETTER

Spontaneous Extrusion of Hand Grenade Fragments From the Face 60 Years After Injury

To the Editor: Retained grenade fragments may slowly migrate in the body over time and thus may not become symptomatic for many years. For instance, Wittich¹ reported a case of a grenade fragment that migrated from the leg 35 years after injury. Similarly, retained shrapnel may migrate several decades after the original injury and has been reported to cause late effects such as biliary obstruction,² bowel perforation,³ and

©2003 American Medical Association. All rights reserved.

Figure. Inflammatory Nodule and Excised Metallic Fragment



A, Arrow indicates inflammatory nodule on chin. B, 4-mm metallic fragment excised from chin nodule.

brain abscess.⁴ These reports describe cases in which the fragment is embedded in a relatively large space within the body. Herein I report a case of fragment extrusion from the face 60 years after the original injury.

Report of a Case. In the fall of 2002, a 70-year-old man complained of an inflammatory nodule that had developed on the left side of his chin during the preceding few days (FIGURE, A). The nodule was firm, well circumscribed, erythematous, and slightly warm. Other areas of the facial skin were healthy, without acne, rosacea, or cysts. The patient reported that a similar nodule had developed over the left mandible 3 months earlier; the nodule had opened spontaneously, with expulsion of a small hard object. The patient was otherwise in good health. Upon excision, the nodule was found to contain a 4-mm metallic fragment (Figure, B).

The patient recalled that as a boy in 1942 or 1943, he had found a hand grenade in his village in Italy. He stated that he had taken the pin out and the grenade detonated in front of him. Although he did have some injuries as a result of this, he stated that they had healed rapidly without medical intervention. The patient's relatives recalled that he did have some wounds on the left side of the face after this incident. The patient did not perform any other activities that would put him at risk for facial injury.

Comment. Exposure to hand grenades may be relatively common among civilians in war zones.⁵ The exact contents of hand grenades may differ, according to the type and destination: defensive or offensive, incendiary, suffocating, or smoke-producing. Defensive hand grenades, such as those used in World War II, generally cause serious injury only in the immediate vicinity of their shock wave. However, they produce hundreds or thousands of tiny missiles that typically weigh less than 200 mg and have diameters of 1 to 4 mm. Thus, they generally have a poor capacity for penetration due to their low mass and unfavorable aerodynamic characteristics.^{6,7} The resulting wound channels are usually of small diameter with little bruising or tearing of tissue, and most missiles are absorbed by soft tissue.

This patient's symptom-free period of 60 years, as well as the relative absence of soft tissue in his face, are both unique

(Reprinted) *JAMA*, September 10, 2003—Vol 290, No. 10 1317

features of this case. It is unclear whether the nearly simultaneous extrusion of these 2 foreign bodies 60 years after the injury was a coincidence or whether it was related to some underlying systemic or environmental factor. Explosive fragments are sometimes discovered as incidental findings during radiological examinations. This case underscores the fact that such fragments may pose a lifelong risk of migration and should be considered in the differential diagnosis of patients who were present in war zones.

Pierre-Dominique Ghislain, MD
Department of Dermatology
Université Catholique de Louvain
Bruxelles, Belgium

1. Wittich AC. Diagnosis and removal of a grenade fragment from the Vietnam war 35 years after injury. *Mil Med.* 2002;167:519-520.
2. Mitchell R, Kerr R, Barton J, Schmidt A. Biliary obstruction secondary to shrapnel. *Am J Gastroenterol.* 1991;86:1531-1534.
3. Symonds RP, Mackay C, Morley P. The late effect of grenade fragments. *J R Army Med Corps.* 1985;131:68-69.
4. Lee JH, Kim DG. Brain abscess related to metal fragments 47 years after head injury: case report. *J Neurosurg.* 2000;93:477-479.
5. Coupland RM. Hand grenade injuries among civilians. *JAMA.* 1993;270:624-626.
6. Karger B, Zweihoff RF, DuChesne A. Injuries from hand grenades in civilian settings. *Int J Legal Med.* 1999;112:372-375.
7. Cooper GJ, Ryan JM. Interaction of penetrating missiles with tissues: some common misapprehensions and implications for wound management. *Br J Surg.* 1990;77:606-610.

CORRECTIONS

Incorrect Data in Table: In the article entitled "Neurologic Manifestations and Outcome of West Nile Virus Infection" published in the July 23/30, 2003, issue of THE JOURNAL (2003;290:511-515), on page 513, Table 1, the following data are incorrect: row "Days from illness onset to presentation, median (range)," column "West Nile Encephalitis (n=8)," 1.5 (-3 to -14) should be 1.5 (-3 to 14); row "Headache," column "West Nile Virus Seronegative Controls (n=23)," 22 (96) should be 22 (100); row "Nausea," column "West Nile Encephalitis (n=8)," 5 (62) should be 5 (63) and column "West Nile Virus Seronegative Controls (n=23)," 17 (74) should be 17 (77); row "Neck pain," column "West Nile Virus Seronegative Controls (n=23)," 17 (74) should be 17 (77); row "Bradykinesia," column "Acute Flaccid Paralysis (n=3)," 2 (67) should be 2 (66); and row "Nuchal rigidity," column "West Nile Encephalitis (n=8)," 5 (63) should be 5 (71).

Incorrect Author Contact and Reference Information: In the Original Contribution entitled "Breast Cancer Following Radiotherapy and Chemotherapy Among Young Women With Hodgkin Disease" published in the July 23/30, 2003, issue of THE JOURNAL (2003;290:465-475), author Lois B. Travis' affiliation in the "Corresponding Author and Reprints" footnote should be Division of Cancer Epidemiology and Genetics, and her e-mail address should be TravisL@mail.nih.gov. Also, the date, volume number, and page number for reference 20 should be 2003;95:971-980.

Incomplete Acknowledgment: In the Clinical Cardiology article entitled "What Clinicians Should Know About the QT Interval" published in the April 23/30, 2003, issue of THE JOURNAL (2003;289:2120-2127), the following individuals participated in a survey conducted in 2002 and/or in a meeting held in August 2000 and should have been listed as academic participants in the Acknowledgment: John Camm, Peter J. Schwartz, Craig January, Michael Kilborn, Christian Funck-Brentano, JoAnn Lindenfeld, Stefan H. Hohnloser, Pedro Brugada, Robert J. Myerburg, Nabil E. El-Sherif, Michael Ackerman, John DiMarco, Sylvia Priori, Lemuel A. Moye, Charles Antzelevitch, Michael R. Franz, and Victoria Vetter.

Long experience has taught us that it is dangerous in the interest of truth to suppress opinions and ideas; it has further taught us that it is foolish to imagine that we can do so. It is far easier to meet an evil in the open and defeat it in fair combat in people's minds, than to drive it underground and have no hold on it or proper approach to it. Evil flourishes far more in the shadows than in the light of day.

—Jawaharlal Nehru (1889-1964)